

Hedgehog Inhibitors (HHI) in the management of multiple basal cell carcinomas (BCCs) in patients with nevoid basal cell carcinoma syndrome (NBCCS): a single centre evaluation of Sonidegib efficacy after Vismodegib discontinuation



Federico Venturi¹, Luciana Trane¹, Flavia Silvestri¹, Biancamaria Zuccaro¹, Jacopo Colombo¹, Vincenzo De Giorgi¹

¹Section of Dermatology, Department of Health Sciences, University of Florence, Viale Michelangiolo 41, Florence, 50121, Italy.

P510

Objective

To demonstrate the efficacy of HHI treatment with Sonidegib in patients with NCBBS who had previously treated with Vismodegib but discontinued it because of its specific adverse effects (AEs).

Methods and materials

We report cases of two patients with confirmed diagnoses of NBCCS. Both patients had undergone multiple surgical excisions and had been treated with oral Vismodegib 150 mg/day for a locally advanced tumor. They both discontinued the therapy due to its specific AEs and are now being treated with oral Sonidegib, which has had better tolerability and a complete response.

Results

Case 1 (Fig. 1): A 54-year-old male with NBCCS was evaluated for a tumor located on the left nasal fold. He had previously undergone multiple surgical excisions and had been effectively treated with Vismodegib 150 mg/day for the same lesion, as well as multiple pigmented BCCs located on the trunk. However, Vismodegib was discontinued after 13 months due to AEs such as G2 muscular cramp with CPK rise, G2 alopecia, and moderate dysgeusia. 48 months after the interruption of Vismodegib, we started oral treatment with Sonidegib 200 mg/day. After 15 months, we detected complete response of the BCC on the face and partial response of the BCCs on the trunk.

Case 2 (Fig. 2): A 74-year-old woman with a long-term history of NBCCS was referred to our clinic for diffuse spreading BCCs located on the back. The patient was given Vismodegib 150 mg/day for 36 months then halted due to AEs of G2 alopecia, G2 muscular spasm, G1 dysgeusia, and nausea. After 18 months of drug discontinuation, 200 mg/day Sonidegib was selected in consideration of the lower risk of drug resistance and the possibility of modifying the dose in case of adverse effects. Sonidegib therapy is being continued with clinical benefit and no drug-related AEs due to high tolerability, and the patient has had a full clinical response.

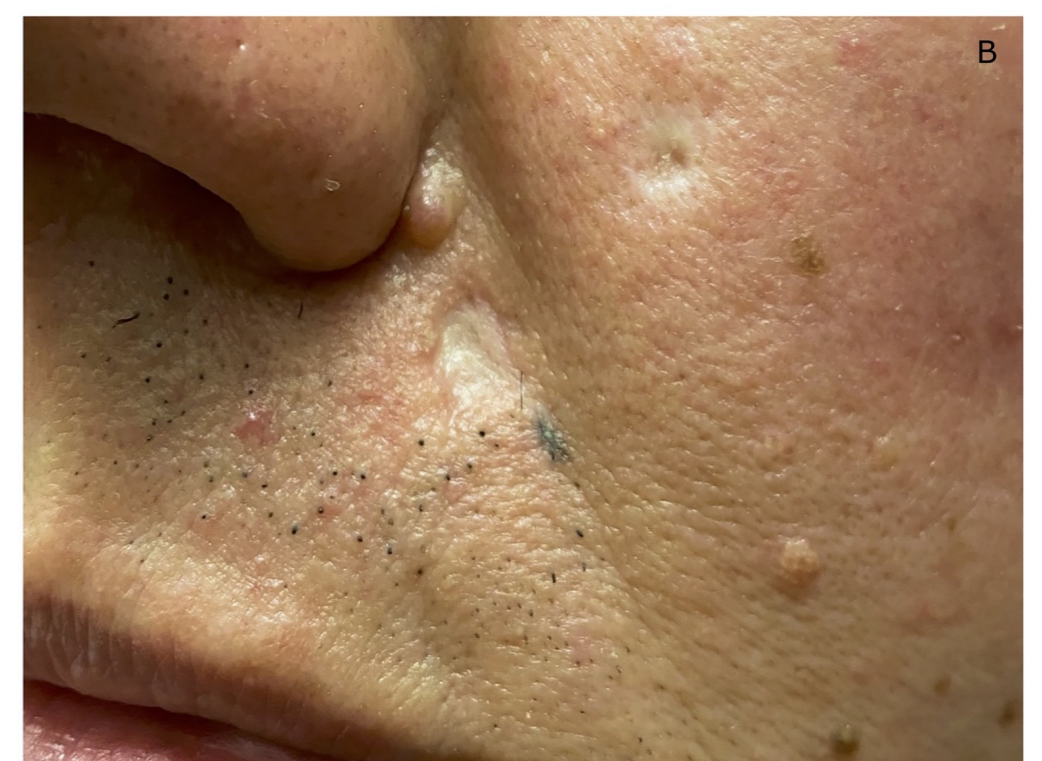
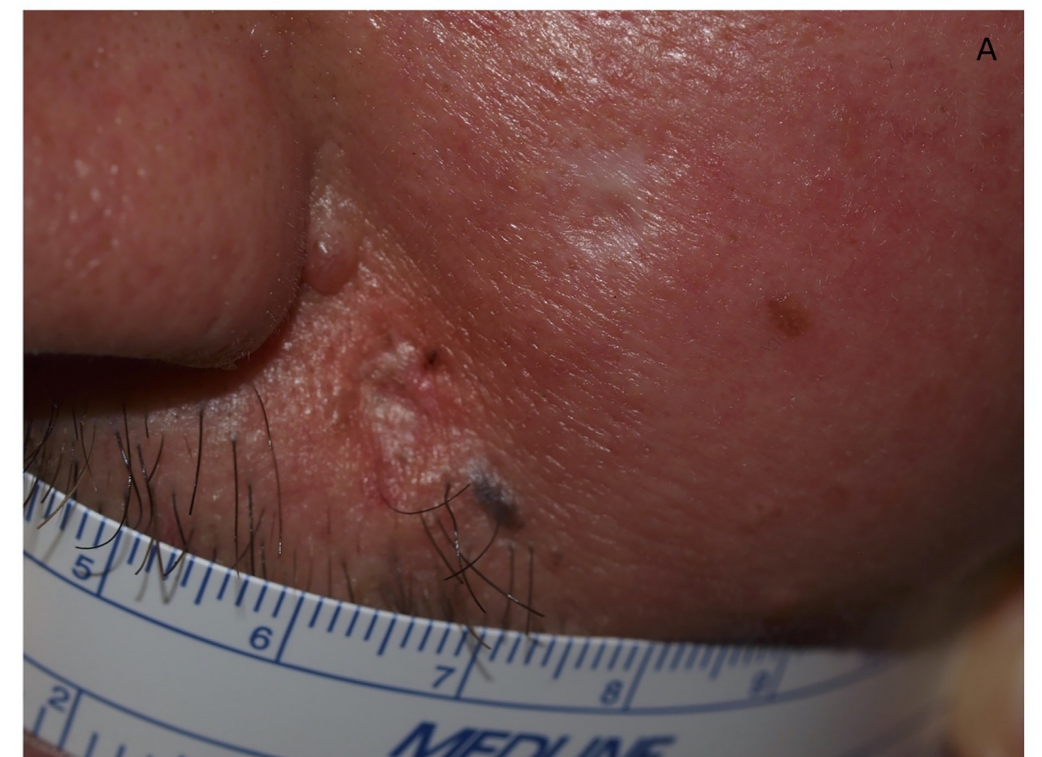
Fig. 1 - Case 1. Clinical presentation of cutaneous BCC located on the left nasal fold: (A) pre-treatment, (B) efficacy after 15 months of treatment with sonidegib 200 mg/die.

Conclusion

The aims of this report was to demonstrate the efficacy of HHI treatment with Sonidegib in patients with NCBBS who had previously treated with Vismodegib but discontinued it because of its specific AEs. As expected, the results show that Sonidegib should be considered in all aspects a first-line treatment for patients with NBCCS not amenable for surgery or radiotherapy, and as sure a second-line option for patients who have previously treated with other HHIs.

References

- (1) Bresler, S. C., Padwa, B. L. & Granter, S. R. Nevoid Basal Cell Carcinoma Syndrome (Gorlin Syndrome). *Head Neck Pathol* 10, 119–124 (2016).
- (2) De Giorgi, V. et al. Treatment of Advanced Basal Cell Carcinoma with Hedgehog Pathway Inhibitors: A Multidisciplinary Expert Meeting. *Cancers (Basel)* 13, 5706 (2021).
- (3) Sekulic, A. et al. Efficacy and safety of vismodegib in advanced basal-cell carcinoma. *N Engl J Med* 366, 2171–2179 (2012).
- (4) Goldberg, L. H. et al. Resolution of odontogenic keratocysts of the jaw in basal cell nevus syndrome with GDC-0449. *Arch Dermatol* 147, 839–841 (2011).
- (5) Lear, J. T. et al. Efficacy and Safety of Sonidegib in Adult Patients with Nevoid Basal Cell Carcinoma Syndrome (Gorlin Syndrome): Results from a Phase 2, Double-Blind, Randomized Trial. *Clin Cosmet Investig Dermatol* 13, 117–121 (2020).

Corresponding Author:

Federico Venturi¹

Ph: +393386070215

E-mail: federico.venturi@unifi.it

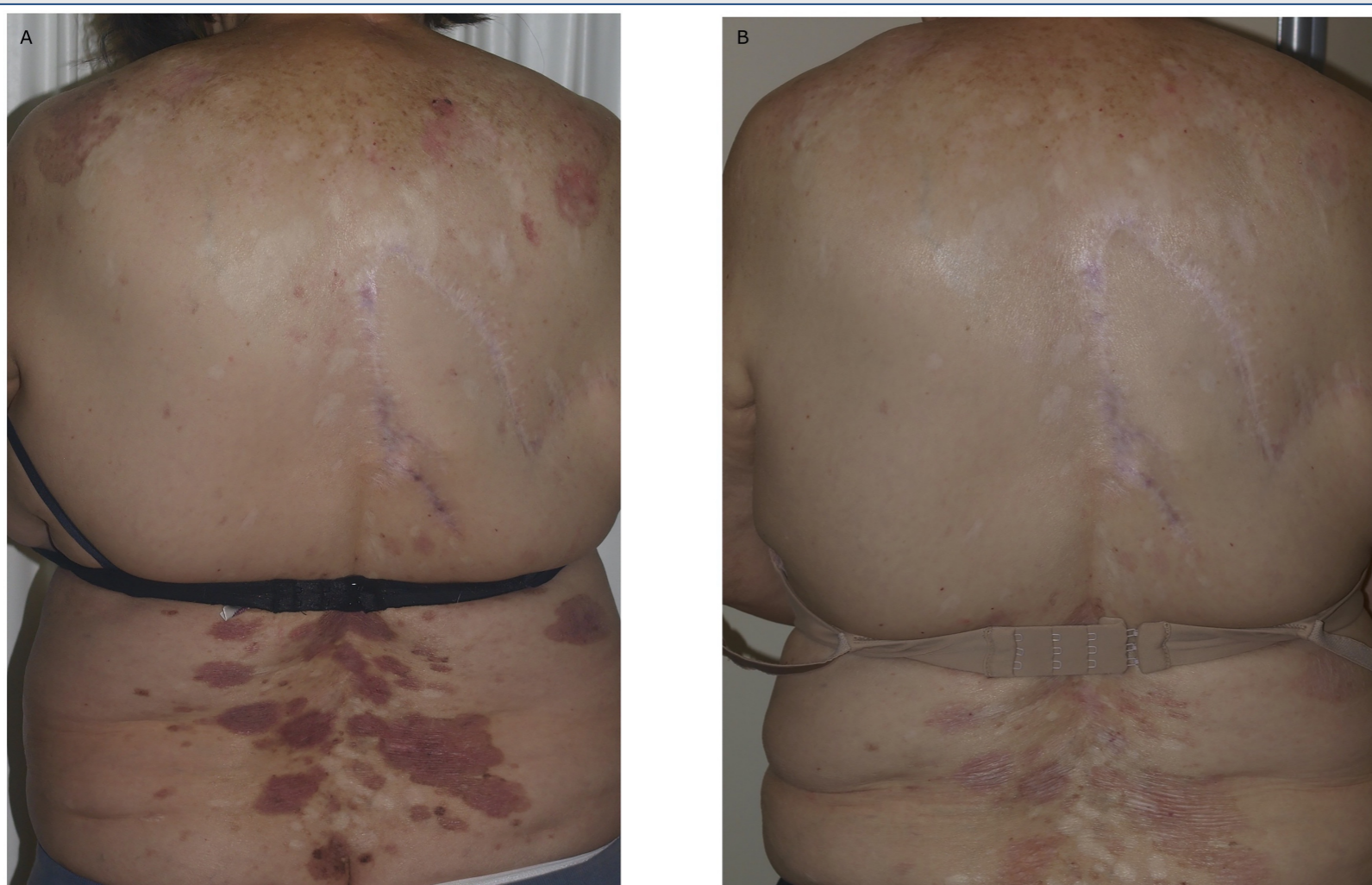


Fig. 2 - Case 2. Clinical presentation of diffuse spreading BCCs located on the back: (A) pre-treatment; (B) efficacy after 6 months of treatment with sonidegib 200 mg/die.